

FootCare Update



Expert care from a professional who cares.

Volume III, No. 4, Revised Winter, 2006

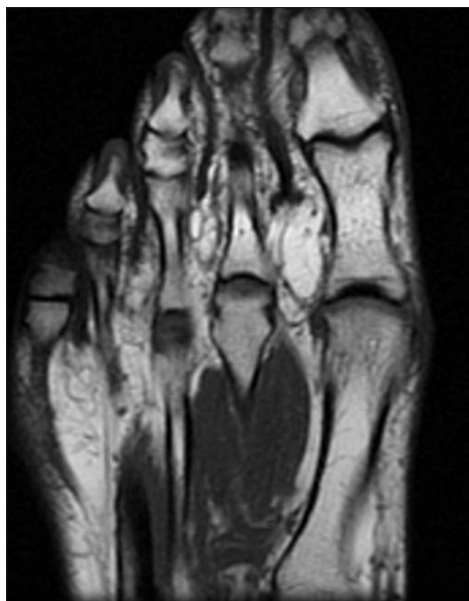
MRI's, CT Scans and X-Rays in Focus: **Basic Tools that help your Podiatric Surgeon diagnose, correct, or reconstruct your bony tissue.**

X-ray pictures are essentially photographs, actually shadow photographs. Dr. Kenneth Leavitt uses x-rays to take pictures of bones deep under the skin, but x-ray pictures are also used by other specialists for looking at the lungs, the bowels and the brain.

X-rays are "light" radiation – invisible light radiation. All light, both the visible and the invisible is composed of "packets" of energy called photons which are measured by wavelength on a scale called a spectrum. Radio wave energy and heat energy (called infrared energy, the kind of photons that night vision goggles look for) are on the left hand side of the spectrum scale. Visible light is in the middle of the spectrum scale. To the right of light on the scale is "ionizing" radiation, beginning with ultraviolet light up to x-radiation and gamma radiation.

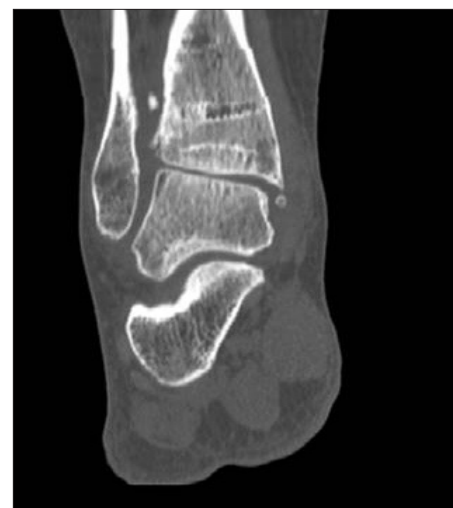Ionizing radiation unlike visible light, infrared radiation and radio waves, has so much energy that it can go deep inside the molecules that make up the living tissues of our bodies and tear them apart. Though the amount of ionizing x-radiation that is used to take pictures of our bodies is very small, the amount that can be used in one year is limited (usually about as much as it takes to take 100

x-ray pictures). And unless it is a life-or-death situation, x-rays are not taken of pregnant women for fear that any amount of x-radiation could cause damage to the cells that turn into body parts.



MRI of forefoot. A trained eye can spot not just bone, but inflammation within the bone.

X-rays are produced in a device called an x-ray tube by a filament not unlike that used in a flash light. And like a flash light, the x-ray light comes out of one side and is shown on a body part behind which is photographic paper. Not unlike a shadow, some of the x-radiation is stopped by

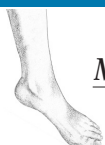

CT scan of ankle and heel from rear. Before and after scans and X-rays assist the surgeon in pre-surgical diagnosis and post-surgical assessment and follow-up.

body, depending upon how dense that body part is or whether or not it contains bone, casting a shadow. The x-rays that get to the plate cause the free floating silver in the photographic paper to stick. That which does not stick gets washed out. Then when a light is shined from behind the photographic plate you can see an image, a negative image of the body part.

Magnetic-Resonance Imaging

MRI – Magnetic-Resonance Imaging – is a non-invasive, diagnos-



Kenneth M. Leavitt, DPM

MEDICINE & RECONSTRUCTIVE SURGERY OF THE FOOT

Doctor of Podiatric Medicine

Fellow, American College of Foot & Ankle Surgeons

Diplomate, American Board of Podiatric Surgery, Certified in Foot Surgery

FootCare Update



MRI's (continued)

tic tool that Dr. Leavitt uses to explore the bones of feet and ankles as well as other body parts such as your back. MRI employs magnetic fields and radio signals to generate pictures. Atomic nuclei, the smallest particles that make-up our bodies, can be asked to give off certain radio signals when a magnet is placed near them, then turned-on then turned-off. The radio signal sent back by bone tissue, tendons, ligament, muscle, etc., depends on the chemical composition of that tissue. Since different tissues have different compositions, the differences in each signal can be turned into a picture by a computer, a picture that looks like our anatomy. To the untrained eye, an MRI picture looks like any normal X-ray, but a trained eye can determine if that anatomy is injured or different than it should normally be.

The important difference between x-ray pictures and CT and MRI is that MRI does not produce any harmful radiation (pregnant women can even have MRIs), and unlike x-ray pictures and CT the MRI can scan for damage or changes to all body tissues. The MRI does not replace x-ray pictures and CT, but it is very helpful when x-ray pictures cannot help.

To take an MRI picture, the patient must lay very still for up to one hour on a flat table in the very center of a large donut-shaped magnet. The magnet will turn on-and-off many times per minute while it generates radio waves from the body. A special radio wave detector will then capture those waves and a kind of super computer will package the information so that it becomes a picture of the body part being examined.

People with pace makers or metal objects in their eyes unfortunately cannot have MRI pictures taken.

CAT Scans

CT and CAT (both the same things) stand for "Computed Tomography" and "Computed Axial Tomography". CT uses x-radiation to take pictures that look like standard x-ray pictures. But, there is one very important difference. Unlike standard x-ray pictures which are two dimensional, CT pictures are created by an x-ray machine that moves around the body while taking pictures. A kind of super computer then decodes the moving pictures to then create a three dimensional image

which is then "sliced-up" into pieces like slices of bread. The computer makes the slices in three different planes (three different directions), just as you can do with a loaf of bread. One can then individually take one slice at a time and examine what the body looks like deep inside.

This technology is a marvel and has allowed doctors to look inside the body without doing surgery. This kind of computer technology is the forerunner of those computers that create MRI images. CT pictures are especially helpful when looking at fractures of bones and are essentially for examining the brain.



Kenneth Martin Leavitt, D.P.M.

MEDICINE & RECONSTRUCTIVE SURGERY OF THE FOOT

New England Baptist Hospital, Suite 390 • 125 Parker Hill Ave. • Boston, MA 02120

TEL: 617-277-3800 • FAX: 617-277-3808

E-MAIL: kenleavitt@earthlink.net • www.bostonfootandankle.com